

PIPS

Improving your endodontic outcomes using laser activated irrigation

Dr. Enrico DiVito

Successful endodontic treatment depends upon maximal debridement and disinfection of the entire root canal system. The root canal system must be shaped to a convenience form that permits adequate cleaning and disinfection by elimination of microbes.¹ The literature is clear that as much as 35% or more of the root canal system remains untouched by any instrumentation technique; that is no filing technique allows instruments to sculpt all canal walls and remove infected dentin.² To decrease the bacterial load and achieve better debridement, irrigation protocols are used prior to obturation. The efficacy of the irrigants to decontaminate canal walls has seen significant improvements recently. Both negative and positive apical pressure irrigation techniques have been surpassed by ultrasonically activated irrigants, photo-activated disinfection and laser-activated irrigants in their ability to improve cleanliness of the canal system.^{3,4}

In particular, the Er:YAG (Lightwalker Er:YAG & Nd:YAG Dental laser, Lasers4Dentistry, Sana Clemente, CA) laser has shown to be effective at removing debris and the smear

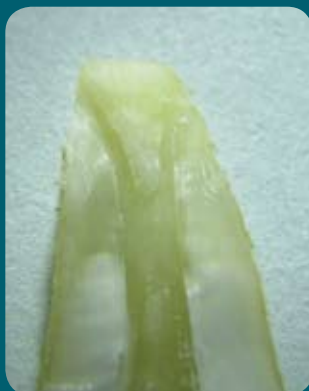layer from canal walls.^{3,4} A final application of the Er:YAG laser with EDTA already present within the canal, after standardized instrumentation, can result in improved cleaning of the canal walls with a higher quantity of open tubules (Figure 1) in comparison to results without the use of the laser.^{3,4}

Figure 2




Close up of tapered and stripped PIPS tip used for laser activated irrigation

Figure 1



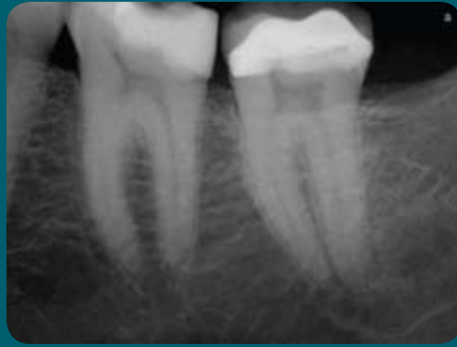Apical 1/3 of root treated with PIPS. Note clean surfaces without any thermal damage



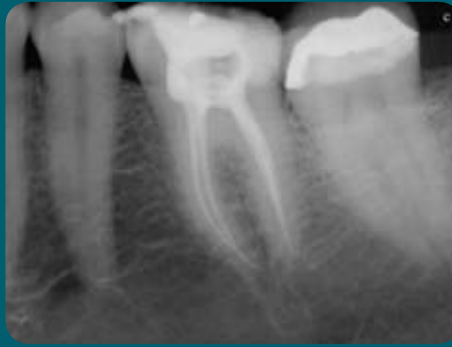SEM of apical 1/3 showing extremely clean dentin tubules post PIPS with no sign of thermal damage

A new application of laser-activated irrigation has been recently introduced. Photon Induced Photo Acoustic Streaming (PIPS™) uses an Erbium 2,940 laser to pulse extremely low energy levels of laser light to generate a photo acoustic shockwave, which streams irrigants throughout the entire root canal system.⁵ Using extremely short bursts of peak power, laser energy is directed down into the canal and the action actively pumps the tissue debris out of the canals while cleaning, disinfecting and sterilizing each main canal, lateral canals, dentinal tubules and canal anastomoses to the apex. This movement of irrigant is achieved without the need to place the radial and stripped laser tip (PIPS™ tip, Figure 2) into the canal

Figure 3



Pre-treatment



Post-treatment obturation after PIPS.
Tooth instrumented to a #25/06 taper. Note the conservative convenience form maintaining more original anatomy of root canal system and reducing the need to use larger file sizes conserving more dentin tooth structure.

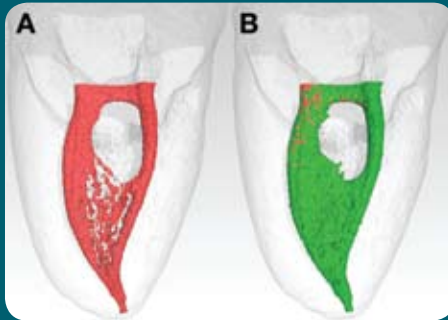
itself, as with other conventional hand and ultrasonic systems. The tip is held stationary in the coronal pulpap aspect of the access preparation only. With the irrigant occupying the entire root canal system, the shock wave created by PIPS™ travels in all directions during activation and effectively debrides and removes organic tissue remnants. Through this laser-activated turbulent flow phenomenon, clinicians following the PIPS™ protocol are not required to place the tip into each canal, thus eliminating the need to enlarge and remove more tooth structure to deliver standard needle irrigation to the smaller and more delicate apical anatomy, commonly seen in the apical one third. The results are canal convenience forms that are more conservative, minimally invasive and biomimetic (Figure 3), preventing the unnecessary removal of tooth structure.

Unlike other laser-activated irrigant techniques, PIPS™ is not a thermal event, rather sub-ablative. Properly executed, PIPS™ creates turbulent photo acoustic agitation of irrigants that move fluids three dimensionally throughout the root canal system even as far as the apical terminus, distant from the radial stripped tip location. By activating the tip in the access cavity and outside the root canal system, the extremely low energy needed to activate the unique PIPS™ tip (20 mJs or less) is below the threshold of ablation for dentin. Ledging and thermal effects that have plagued the widespread use of other laser systems is completely avoided at the energy levels used by the PIPS™ technique.^{5,6}

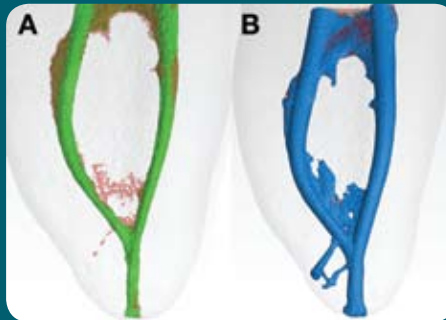
Recent testing, performed at the University of Tennessee by Dr. Adam Lloyd, Chairman of the Department for Endodontics, objectively confirmed the improved cleaning and debridement of organic and inorganic tissue left by instrumentation. Micro-computed tomography scans were used to assess before and after volumetric change in the internal intaglio of lower first molars treated with PIPS™ protocol (Figure 4). Sequential slicing beginning at 6 mm from the apex and moving down to the last 2 mm demonstrated that all slice images showed significant improvements after PIPS™. The importance of these findings is far reaching. PIPS™ now offers the dentist a less technique sensitive, minimally invasive and time reducing method for irrigating and preparing endodontic root canal systems. Because PIPS™ has demonstrated its ability to decontaminate and debride areas that files and instrumentation cannot reach, success rates rise and retreatment for past failures is possible.⁷ PIPS™ is also helpful in locating and helping negotiate calcified canals. PIPS™ is a valuable additional tool in the treatment of endodontics regardless of the shaping and obturation system used by the dentist.

During the last 8 years of research, testing and development of PIPS™ I have seen a drastic improvement in the laser technology used in endodontics. This method is available now and is being used by many, not only in the US and Canada, but even in Europe. I encourage you to take the time to learn more about PIPS™ and start improving the outcomes of your endodontic treatments.

Figure 4



Mandibular molar canal system showing isthmus before (image A, red canal) PIPS laser activated irrigation. Areas of organic tissue and debris from instrumentation have been completely eliminated, as highlighted by post-PIPS image (image B, green canal).



Mandibular molar with canal preparation to a size 30/04 (image A, green canal) obturated with nano-particle BC Sealer (Brasseler USA, Savannah, Ga.) and single cone obturation (image B, blue).

References:

1. Clark D, Khademi JA. "Case studies in modern molar endodontic access and directed dentin conservation" *DentClin NorthAm.* 2010;54:275-289
2. Peters OA, Schonenberger K, Laib A. Effects of four Ni-Ti preparation techniques on root canal geometry assessed by micro-computed tomography. *International Endodontic Journal*
3. George R, Meyers IW, Walsh LJ (2008) Laser activation of endodontic irrigants with improved conical laser fiber tips for removing smear layer in the apical third of the root canal. *J Endod* 34:1524-1527
4. de Groot SD, Verhaagen B, Verstuis M, Wu MK, Wesselink PR, van der Sluis LW (2009) Laser-activated irrigation within root canals: cleaning efficacy and flow visualization. *Int Endod J* 42:1077-1083
5. Li Z., Code JE., Van De Merwe WP. Er:YAG Laser ablation of enamel and dentin of human teeth: determination of the ablation rates at various fluences and pulse repetition rates. *Lasers in Surgery and Medicine.* 1992, 12:625-630.
6. Majaron B, Lukac M, Sustercic D, et al. Threshold and efficiency analysis in Er:YAG laser ablation of hard dental tissue. *Proc SPIE.* 1996;2922:233-242.
7. DiVito, E., O.A. Peters, and G. Olivi, Effectiveness of the erbium:YAG laser and new design radial and stripped tips in removing the smear layer after root canal instrumentation. *Lasers Med Sci.* 2012. 27(2): p. 273-80