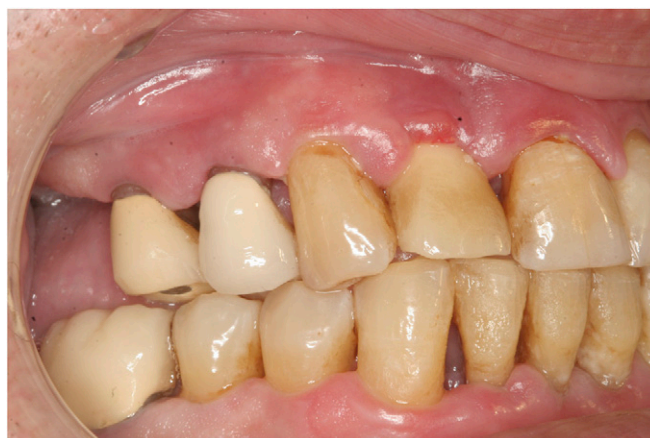
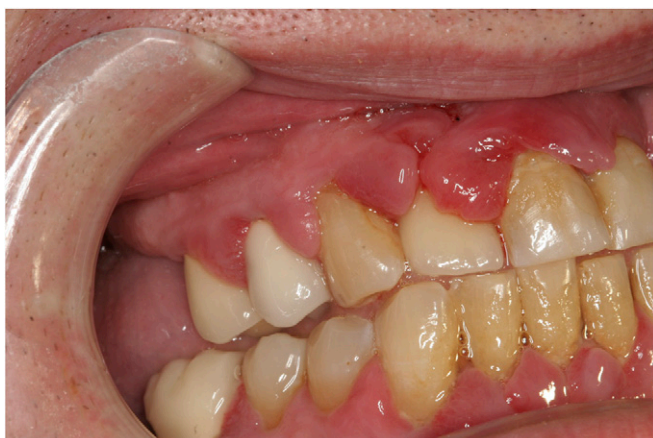
## Current Advances in the Use of Lasers in Periodontal Therapy: A Laser-Assisted New Attachment Procedure Case Series

I. Stephen Brown\*†‡§



**Introduction:** The focus of periodontal surgical procedures has shifted over the past three decades from a philosophy based on resection (subtractive) to one of regeneration of lost tissues (additive). This shift has had particular significance in cases of advanced periodontitis. When a patient presents with severe attachment loss, regeneration cannot take place until the etiologic factors have been effectively managed or reversed and the disease progression arrested. Traditional surgical techniques have been successful in facilitating access and addressing the goal of “pocket elimination.” However, such surgical methods often result in unpleasant side effects, which can be painful and disfiguring. Clinicians have come to accept previous tissue breakdown as often irreversible. Additionally, the theory behind conventional pocket elimination was to produce an environment that promoted ongoing disease control by facilitating personal oral hygiene. At its best, traditional pocket surgery often falls short of achieving these goals and objectives. Additionally, conventional resective surgical techniques do not adequately address esthetic concerns, whereas surgical techniques, which are directed toward regeneration, have as their ideal outcome the preservation and/or restoration of lost periodontal tissues.

**Case Series:** This case series presents six clinical cases illustrating favorable results using laser-assisted new attachment procedure. In all cases, mobility and other manifestations of occlusal pathology were assessed. Occlusion was carefully addressed and managed using a combination of procedures.

**Conclusions:** The results of recent research on a specific free-running, pulsed neodymium-doped:yttrium–aluminum–garnet (Nd:YAG) laser suggest that this laser provides a viable alternative to traditional periodontal surgery. Properly applying the laser has been shown to produce less bleeding, swelling, and discomfort. The Nd:YAG laser appears to address the cause of periodontal disease rather than the effects by specifically targeting identifiable periodontal pathogens. Regeneration of periodontal tissues is the gold standard by which dentists measure treatment effectiveness. Evidence has emerged that the Nd:YAG laser provides an enhanced method for achieving this elusive goal while eliminating many of the negative sequelae, which have been historically associated with conventional pocket elimination surgery. It should be noted that the information in the paper does not refer to all Nd:YAG lasers, but to one specific type of Nd:YAG laser. There are specific differences between individual YAG lasers, and this one is unique. *Clin Adv Periodontics* 2013;3:96-104.

**Key Words:** Nd-YAG lasers; periodontal attachment loss; periodontal pocket; periodontal regeneration.

\* Department of Periodontics, University of Pennsylvania School of Dental Medicine, Philadelphia, PA.

† Department of Periodontology and Dental Implantology, Temple University School of Dentistry, Philadelphia, PA.

‡ Department of Dental Medicine, Dental Implant Center, Albert Einstein Medical Center, Philadelphia, PA.

§ Private practice, Periodontics and Dental Implants, Philadelphia, PA.

Submitted August 16, 2012; accepted for publication November 18, 2012

doi: 10.1902/cap.2013.120087

### Background

Donna E. Shalala, former Secretary of Health and Human Services, stated that: 1) oral health means much more than healthy teeth; 2) oral health is integral to general health; 3) most adults show signs of periodontal or gingival diseases, and severe periodontal disease (measured as 6 mm of periodontal attachment loss [AL]) affecting  $\approx 14\%$  of adults aged 45 to 54 years old; 4) 23% of 65 to 74 year olds have severe periodontal disease; and 5)  $\approx 30\%$  of adults 65 years and older are edentulous.<sup>1</sup>

Although extremely difficult to quantify, it is widely accepted that 70% to 80% of Americans have some form of periodontal disease, and as much as 50% of these may be characterized as moderate to severe. Anecdotal data suggest that <4% of patients with periodontal disease are receiving treatment in the United States. Allowing for the possibility that these numbers may be understated, there seems to be no disagreement that periodontal disease represents a world-wide health hazard and is the most significant cause of tooth loss.

From the foregoing, it may be inferred that individuals with periodontal disease are not seeking or receiving adequate periodontal care. What are the factors that contribute to the low incidence of periodontal therapy being sought or rendered? These statistics are especially troubling despite recently emerging data suggesting that periodontal disease has been associated with a plethora of life-threatening systemic health conditions.

The answer may be attributed to the general perception that periodontal treatment, especially surgical, is invasive, often with unpredictable and undesirable outcomes and onerous, long-term adverse effects. In addition, surgical intervention is thought to be time consuming, costly, and painful.

Progressive increase in probing depth (PD) has been directly correlated with AL. It is noteworthy that the focus of corrective periodontal surgery has shifted over time, from an emphasis on resection to achieve pocket elimination to more current thinking based on regeneration of lost tissues. This change in focus has particular significance in patients exhibiting advanced periodontitis. As a resident in periodontology in the 1970s, Dr. D. Walter Cohen (paraphrased) prophesied that, "In the future, the management of periodontal disease will focus on plastic and reconstructive procedures, 'additive' rather than resective 'take away' procedures."<sup>2</sup> This was a significant departure from widely accepted theories regarding conventional treatment.

Historically, the procedure of choice for pocket elimination was the gingivectomy. Pierre Fauchard first described this surgical approach in the 18th century.<sup>3</sup> Various modifications were promoted throughout the early 20th century. However, the efficacy of the gingivectomy procedure came to be questioned. The limitations included an inability to address bony deformities and undesirable postoperative sequelae. Negative outcomes included denuded, sensitive, and caries-prone teeth. Results included exposed root surfaces, large spaces between teeth, and partial or total loss of attached gingiva. For all of these reasons, the gingivectomy procedure was found to be deficient.

In 1949, Schluger<sup>4</sup> provided a treatise on osseous resection that described enhanced methods for accessing the alveolar bone, enabling alteration of bony irregularities and defects long associated with advanced periodontal disease. In 1954, Nabers<sup>5</sup> recommended an alternative approach to alleviate the perceived disadvantages of the available pocket-elimination procedures. He promulgated elevation of a full-thickness mucoperiosteal flap and relocating of the attached gingiva. Naber's approach enhanced access, preserved

keratinized masticatory mucosa, and addressed pockets extending into the alveolar mucosa.

Notwithstanding their success in pocket elimination, these methods were still associated with undesirable post-treatment sequelae, such as "long teeth," interproximal spacing, and marked changes in phonetics and esthetics. For these and other reasons, patients were extremely reluctant to accept traditional periodontal flap surgery. Conversely, the non-surgical alternative of traditional scaling and root planing (SRP) did little to eliminate pathologic pockets, much less repair or regenerate lost tissues.

Historically, the gold standard of periodontal therapy has been regeneration, loosely defined as the natural renewal of lost tissue or a component part. The specific requirements for regeneration or new attachment include new bone, new periodontal ligament (PDL), and new cementum. True regeneration must further demonstrate attachment of connective tissue (CT) fibers (Sharpey's), originating from the principle fibers of the PDL, extending from the walls of the alveolus and inserting in the cementum of the tooth root.

Because traditional resective procedures did not predictably produce the classic elements of regeneration, other methods were introduced with varying but often unpredictable outcomes. These have included bone grafting procedures using autogenous bone, allografts, xenografts, alloplasts, and synthetic materials.

Several researchers reported on guided tissue regeneration (GTR)<sup>6,7</sup> in the early 1980s. This modality relied on the use of barrier membranes in conjunction with flap surgery. The objective of the barrier was to create space and retard apical downgrowth of the gingival epithelium. It was theorized that the exclusion of these tissues would permit the more slowly growing bone and the requisite reattachment of the PDL fibers to occur.

Modifications of the classic GTR procedure included use of various barriers. The earliest membranes were non-resorbable, typically expanded polytetrafluoroethylene. However, this approach mandated a subsequent surgery to remove the membrane. The requirement of a second surgical procedure imposed yet another obstacle preventing patients from choosing the GTR technique. This, in turn, led to the development of other resorbable collagen and synthetic membranes.

Recent enhancements to regenerative procedures have included the use of biologic mediators and tissue engineering. These surgical enhancements are said to stimulate more rapid healing and jump start the process of regeneration. Such biologic products may be obtained directly from humans and animals or synthetically created in the laboratory. Two examples of these include enamel matrix proteins<sup>8</sup> obtained from developing teeth and platelet-rich plasma derived from processing human blood.

The concept underlying the use of these and other similar products is their ability to stimulate the release growth factors, an example of which is platelet-derived growth

<sup>8</sup> Emdogain, Straumann, Andover, MA.

factor (PDGF). Recently, recombinant human (rh) PDGF-BB has become available as a commercial product for clinical use in periodontics. It is marketed as growth-factor enhanced matrix.<sup>¶</sup>

In the ongoing search for predictable regeneration, material has been developed that contains rh bone morphogenetic protein (BMP-2),<sup>#</sup> a genetically engineered version of a naturally occurring protein, capable of initiating bone growth. The discovery and development of the concept and the potential uses of BMP in medicine originated with the research of Urist<sup>8</sup> and Urist and Strates<sup>9</sup> almost 50 years ago.

The search for the “holy grail” of periodontal regeneration continues. Notwithstanding all of advances referenced above, predictable regeneration of periodontal tissues continues to be an enigma within a conundrum. Puzzling, contradictory, and controversial because of an incomplete understanding of its mechanism, it remains a lightening rod of ongoing controversy.

For more than a generation, dentists have used lasers for a variety of applications in clinical dental practice. More than 10 years ago, Gregg and McCarthy<sup>10,11</sup> published research on the use of a specific free-running pulsed neodymium-doped:yttrium–aluminum–garnet (Nd:YAG) laser for the treatment of periodontal disease. First conceived and developed in the 1990s, they later proposed its use for achieving bone regeneration.<sup>10,11</sup> They developed a specific protocol, laser-assisted new attachment procedure (LANAP), with research-proven operating parameters. LANAP received Food and Drug Administration clearance in 2004.<sup>12</sup> An Nd:YAG laser<sup>\*\*</sup> was developed that operates at a wavelength of 1,064 nm to deliver the therapeutic LANAP.

The formal definition developed for LANAP is “cementum-mediated new attachment to the root surface in the absence of a long junctional epithelium.”<sup>12</sup> Specific aspects of LANAP<sup>13</sup> are as follows: 1) a thin 0.3 to 0.4 laser fiber permits easy access deep into the periodontal pocket without the need to surgically elevate a flap; 2) selective photothermolysis is generated to remove diseased, infected, and inflamed pocket epithelium while preserving healthy adjacent CT; 3) precise tissue ablation and antiseptic hemostasis by varying the energy density of the laser, pulse duration, and repetition; 4) operating at a wavelength of 1,060 nm, laser light energy is attracted to pigmented tissues and colored bacteria causing the destruction of periodontal pathogens; 5) changing the settings of the laser completes the debridement process and achieves hemostasis with a fibrin clot; 6) closure is achieved without sutures or surgical glue, relying on the fibrin clot and tissue compression; and 7) management of occlusal pathology is accomplished with occlusal adjustment and splinting of teeth with greater than Class II mobility.

The potential for regeneration is facilitated by: 1) delivering intense, precise, and selective energy to the affected area (periodontal pocket), without damage to adjacent tissues; 2) being bactericidal to pigmented periodontal pathogens; 3) sealing the pocket orifice with a “thermal fibrin clot”; 4) creating a physical barrier (such as a barrier

membrane), preventing downgrowth of epithelium; and 5) promoting healing from the bottom up rather than the top down by stimulating the release of pluripotential cells from the PDL and alveolar bone.

Despite the initial controversy surrounding aspects of LANAP, the procedure represents a precise treatment protocol, combining the best aspects of laser-mediated surgery with the well-established principles of traditional periodontal therapy. The goals are the same, but the application of methods for achieving these objectives is markedly different. In all cases, consistent with LANAP, aggressive debridement of all pockets/defects is accomplished with high-power piezo scalers.

Conversely, notwithstanding that the goals parallel each other, there are many substantial benefits attributed to LANAP therapy when compared to conventional periodontal surgery. The benefits have been described as less invasive and less traumatic, minimal postoperative discomfort, minimal recession and thermal sensitivity, quicker healing, and equally successful results treating dental implants and natural teeth.

In one of the largest human histology studies, Yukna et al.<sup>14,15</sup> were the first to publish and prove incontrovertibly the positive results of LANAP therapy when compared to conventional periodontal treatment. The study was university based, longitudinal, controlled, prospective, and masked. The results showed unequivocally that 100% of the teeth treated with LANAP formed new attachment as opposed to 0% of the control teeth. More recently, in 2012, Nevins et al.<sup>16</sup> reported another landmark human block study demonstrating highly successful outcomes of patients treated with LANAP in cases of extreme periodontitis.

What follows are examples of various clinical cases illustrating favorable results using LANAP. In all cases, in accordance with LANAP, mobility and other manifestations of occlusal pathology were assessed. The occlusion was carefully addressed and managed using a combination of procedures.

## Clinical Presentation, Management, and Outcomes

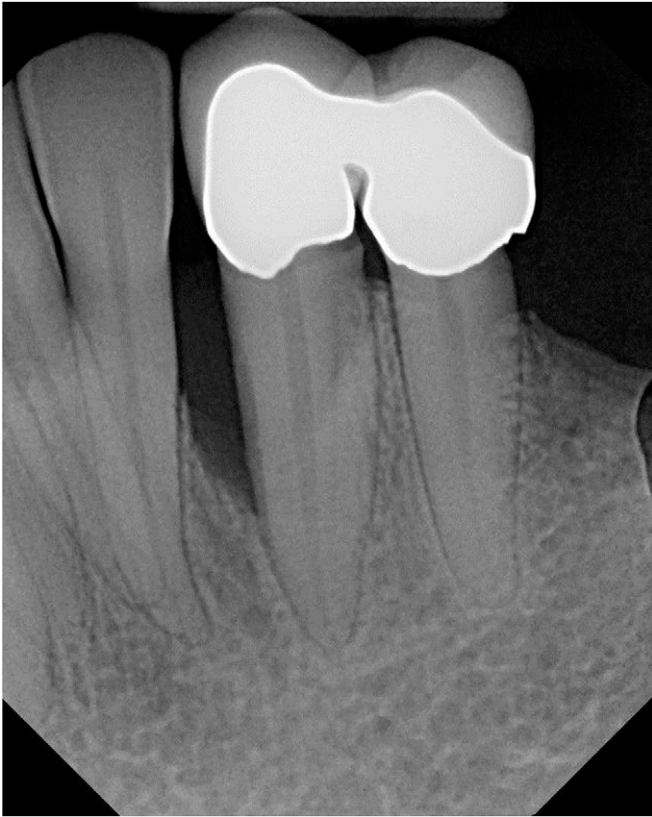### Case 1

This is the case of a middle-aged female who presented to a private practice (Dr. Murray Rabalais, Houma, Louisiana) with a 9-mm pocket, exhibiting a marked osseous defect on the mesial aspect of tooth #22 (Fig. 1). Significant bleeding on probing (BOP) was noted, with a mild diastema between teeth #22 and #23. Medical history was unremarkable and non-contributory. The benefits, risks, alternative treatments, and possible consequences of non-treatment were discussed with the patient, and it was decided to provide LANAP.

¶ GEM 21S growth factor-enhanced matrix, Osteohealth, Shirley, NY.

# INFUSE Bone Graft, Medtronic, Minneapolis, MN.

\*\* PeriLase MVP-7 laser, Millennium Dental Technologies, Cerritos, CA.



**FIGURE 1** Case 1. Preoperative, standard clinical periapical radiograph (courtesy of Dr. Murray Rabalais).

Sequential standard radiographs during the postoperative period illustrated evidence of progressive repair and suggested ongoing regeneration (Fig. 2). Probing was within normal limits, without observable pathology, and the diastema had spontaneously closed. Clinical photographs were not available.

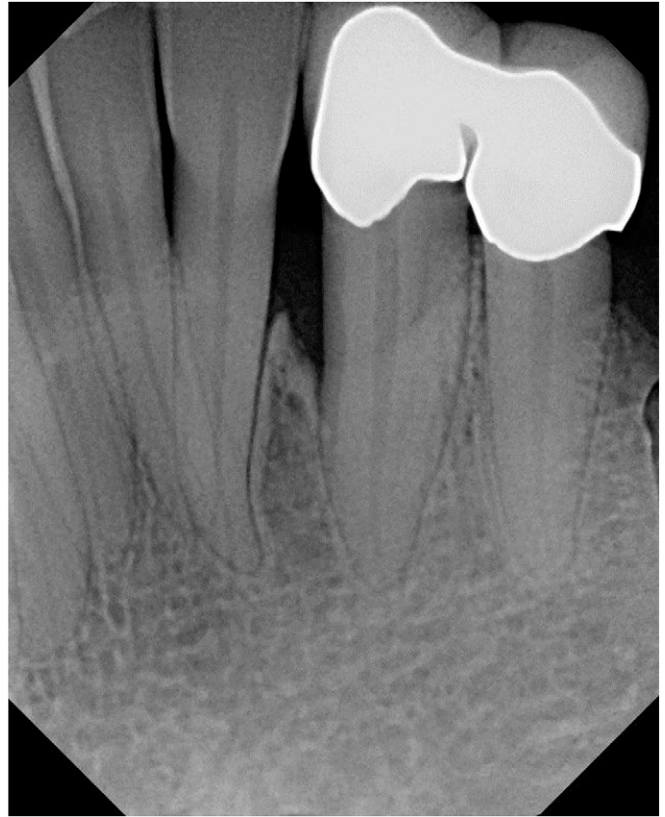### Case 2

A 34-year-old male presented to a private practice (Dr. Murray Rabalais) with a vertical osseous defect on the distal aspect of tooth #18 (Fig. 3). The defect measured 8 mm on the disto-facial aspect and 5 mm on the disto-lingual aspect. The location of the defect, in the absence of other significant periodontal disease, suggested that the pathology might have developed subsequent to previous extraction of tooth #17. There was marked BOP, suggesting the presence of pathologic tissue, most likely of bacterial origin, secondary to the development of the defect. Medical history was unremarkable and non-contributory. The benefits, risks, alternative treatments, and possible consequences of non-treatment were discussed with the patient, and it was decided to provide LANAP.

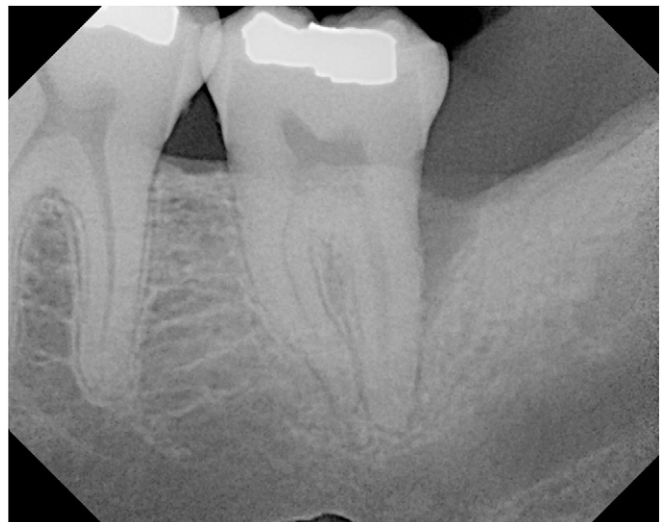After LANAP, probing was within normal limits, and there was complete absence of BOP (Fig. 4). Clinical photographs were not available.

### Case 3

A 30-year-old male presented to a private practice (Dr. Braden Seamons, Honolulu, Hawaii) with an implant replacing tooth

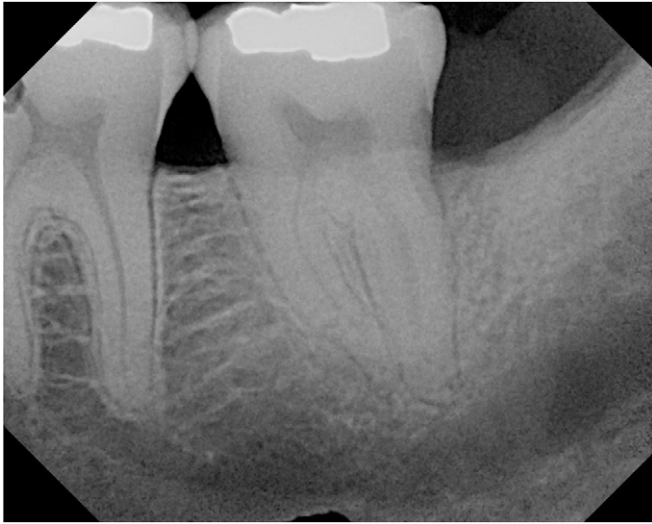

**FIGURE 2** Case 1. Postoperative, standard radiograph at 10 months (courtesy of Dr. Murray Rabalais).

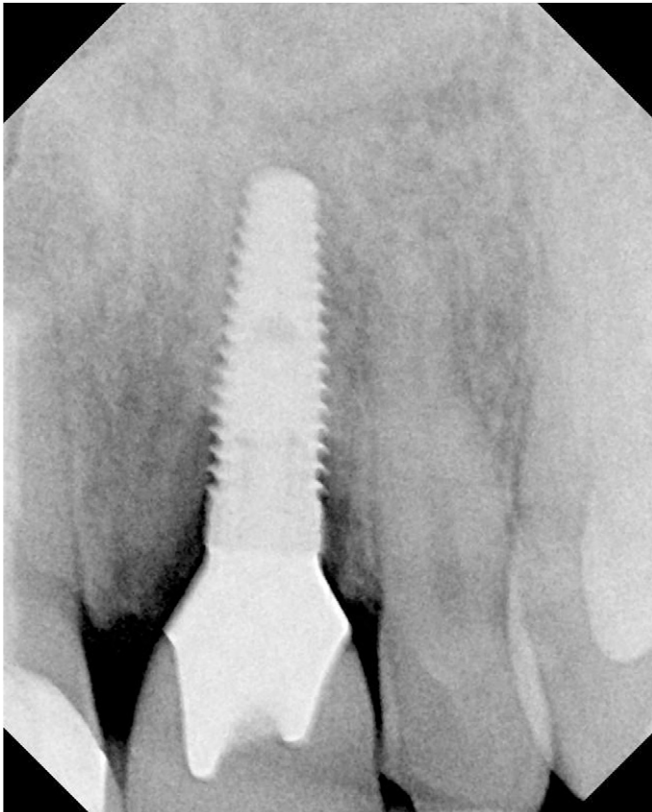

**FIGURE 3** Case 2. Preoperative, standard periapical radiograph (courtesy of Dr. Murray Rabalais).

#9 that had been placed several years previously (Fig. 5). Pathologic loss of crestal bone was noted, with PDs of 6 mm on the mesial aspect and 5 mm on the distal aspect. Accurate measurements may have been greater, but the width of the probe precluded reaching the base of the defects. Medical history was unremarkable and non-contributory. The benefits, risks, alternative treatments and possible consequences of non-treatment were discussed with the patient, and it was decided to provide LANAP.



**FIGURE 4** Case 2. Postoperative, standard radiograph at 15 months (courtesy of Dr. Murray Rabalais).

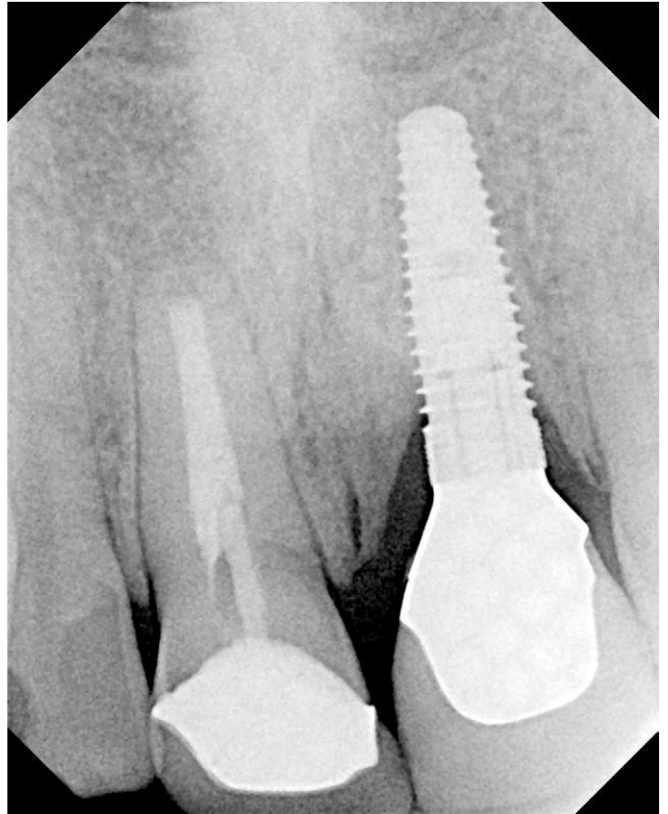


**FIGURE 5** Case 3. Preoperative, standard periapical radiograph (courtesy of Dr. Braden Seamons).

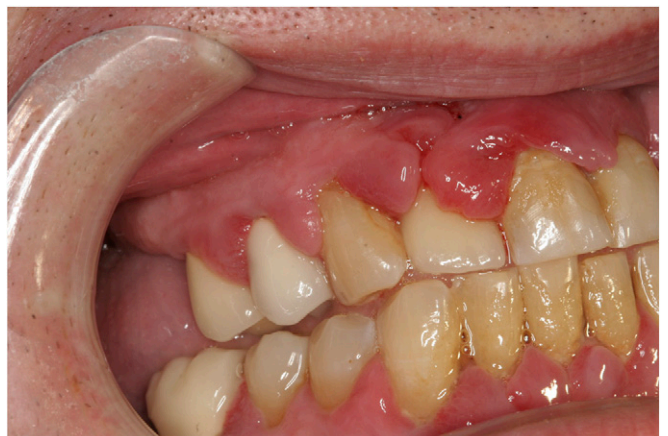After LANAP, probings were within normal limits with no evidence of ongoing periodontal pathology (Fig. 6). Clinical photographs were not available.

**Case 4**

A 56-year-old male presented to a private practice (ISB, Philadelphia, Pennsylvania) with severe, progressive periodontal disease (Fig. 7). Medical history revealed type II diabetes and a variety of cardiovascular problems, including



**FIGURE 6** Case 3. Postoperative, standard periapical radiograph at 3 months (courtesy of Dr. Braden Seamons).

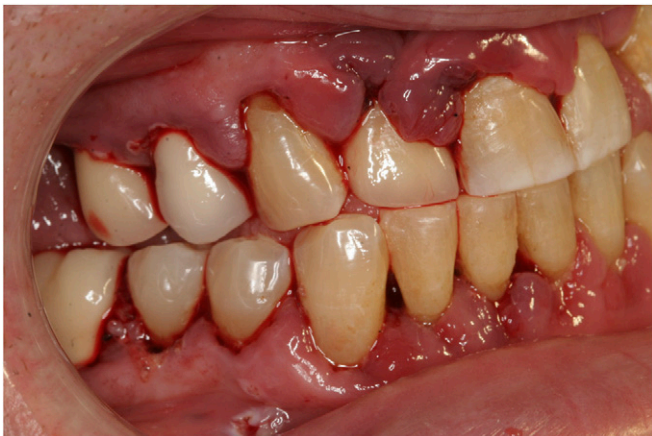

**FIGURE 7** Case 4. Preoperative clinical appearance (ISB).

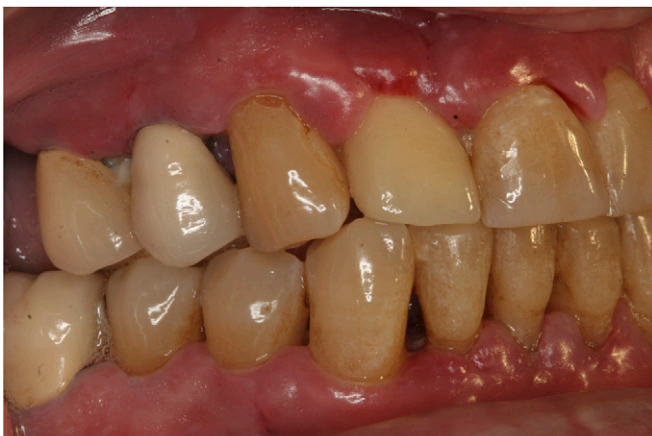the presence of a pacemaker. Significantly, he was taking warfarin.<sup>††</sup> His medical history and drug regimen were clearly contributory to the observed symptoms of generalized severe, progressive periodontal disease.

The patient expressed a significant desire to save his teeth. Several previous periodontal consultations only offered SRP, in conjunction with conventional flap surgery. He declined this treatment approach, expressing a previous history of similar treatment. The benefits, risks, alternative treatments, and possible consequences of non-treatment

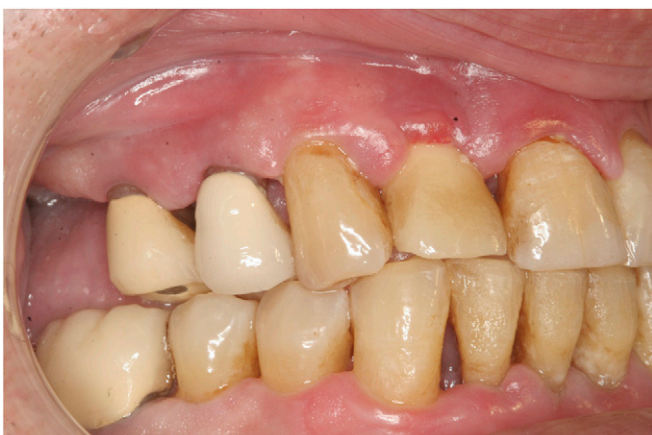<sup>††</sup> Coumadin, Bristol-Myers Squibb, New York, NY.



**FIGURE 8** Case 4. Tissues immediately after surgery. Note the marked absence of bleeding. Early, generalized thermal fibrin clotting is exhibited at the gingival margins (ISB).



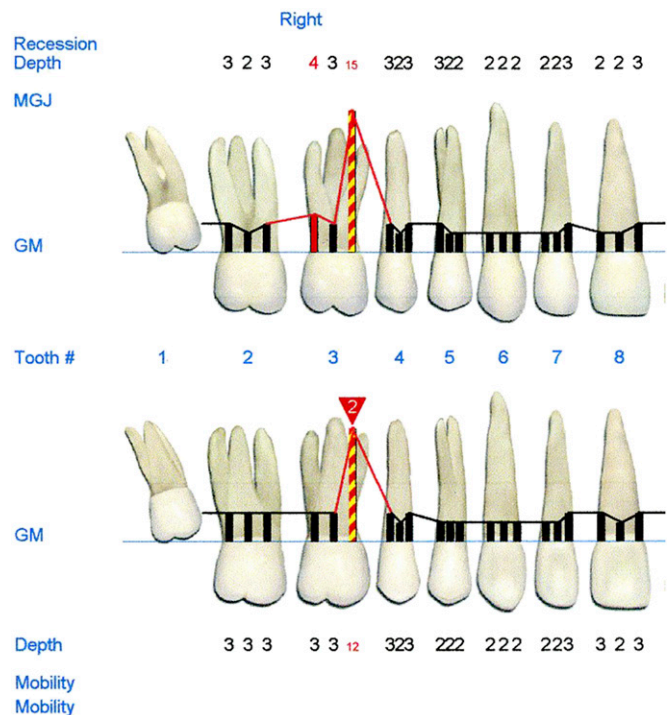
**FIGURE 9** Case 4. Substantial healing and alteration of the gingival tissues at 1 week despite the presence of interproximal plaque deposition (ISB).



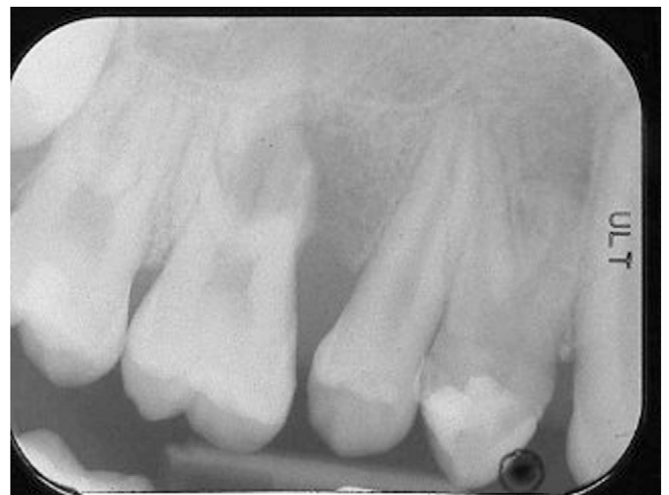**FIGURE 10** Case 4. Three-week healing. Note ongoing positive changes in gingival color and architecture, with minimal shrinkage and root exposure (ISB).

were discussed with the patient, and it was decided to provide LANAP (Fig. 8).

Figures 9 and 10 illustrate healing at 1 and 3 weeks, respectively. Gentle manual brushing only was permitted at 7 to 10 days to preserve the integrity of the fibrin clot.



**FIGURE 11** Case 5. Digital charting illustrating 12 to 15 mm PD (image courtesy of Dr. Matthew Heaton).

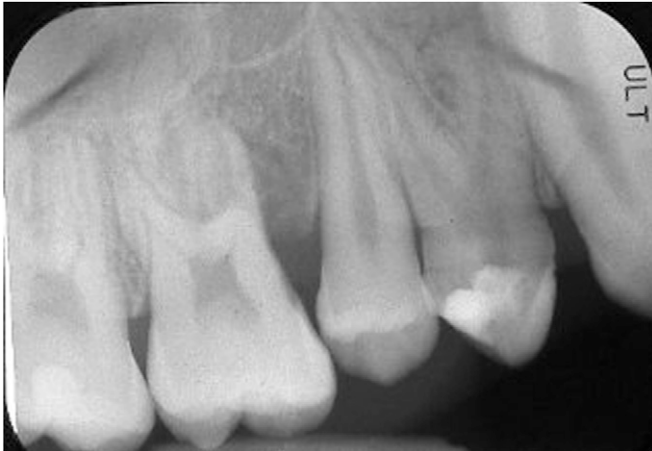

**FIGURE 12** Case 5. Initial standard periapical radiograph at presentation showing severe AL and invasion of the trifurcation (courtesy of Dr. Matthew Heaton).

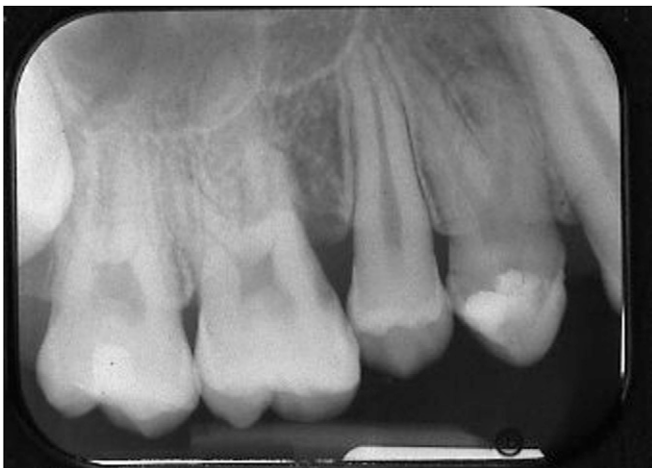Plaque control was supplemented by twice-daily chlorhexidine rinse. At 1 month, the patient reported a marked reduction in blood glucose levels.

### Case 5

A 13-year-old male presented to a private practice (Dr. Matthew Heaton, Knoxville, Tennessee) with persistent soreness in his maxillary right molar which had been occurring for 6 to 8 months. Clinical findings revealed advanced AL, with 12 to 15 mm pocketing (Fig. 11), bleeding, suppuration, and a Class II trifurcation involvement (Fig. 12). The tooth was clinically vital, which precluded a diagnosis of an endodontic-periodontic lesion. The benefits, risks,



**FIGURE 13** Case 5. Standard radiograph at 4 months (courtesy of Dr. Matthew Heaton).



**FIGURE 14** Case 5. Standard radiograph at 11 months (courtesy of Dr. Matthew Heaton).

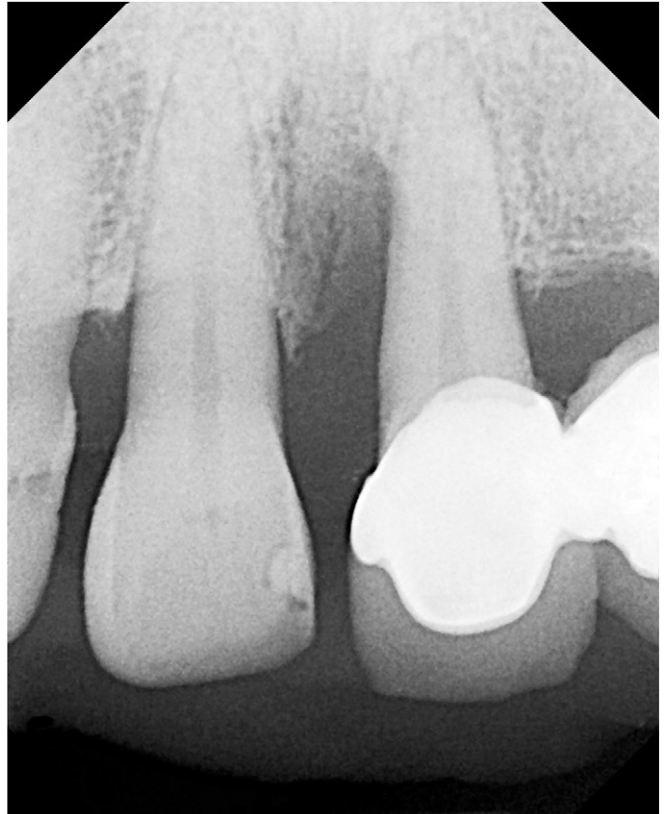alternative treatments, and possible consequences of non-treatment were discussed with the patient, and it was decided to provide LANAP.

Radiographs were taken at 4 and 11 months (Figs. 13 and 14). Attachment levels at 11 months recorded a 7- to 11-mm attachment gain, with closure of the mesial furcation defect and radiographic evidence of bone regeneration. Clinical photographs were not available.

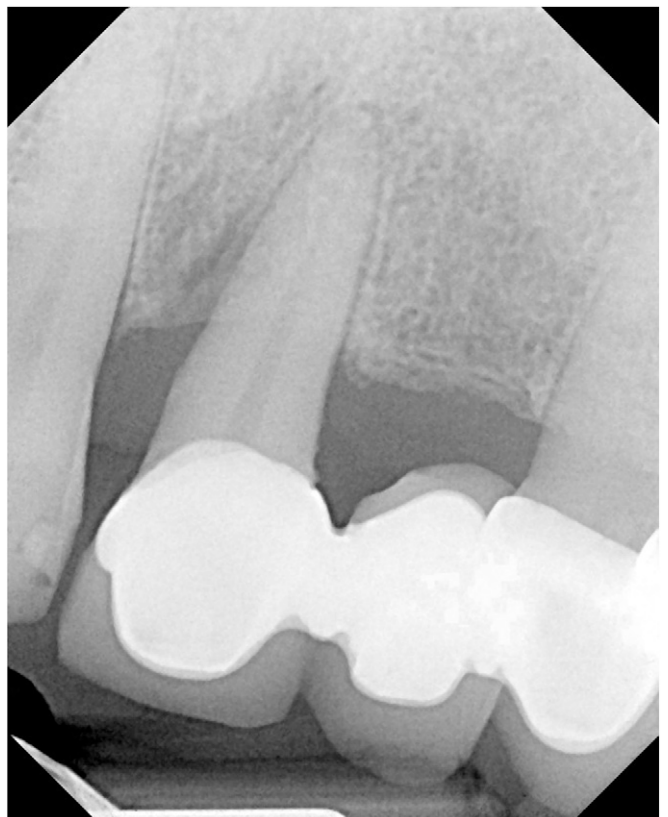### Case 6

A 46-year-old male presented to a private practice (Dr. Braden Seamons) for periodontal treatment, with a defect on the mesial aspect of tooth #9 (Fig. 15). Clinical findings revealed a 9-mm pocket, of which 5 mm was subcrestal. There was distinct BOP, and clinical observations included edema and alterations in gingival architecture. The benefits, risks, alternative treatments, and possible consequences of non-treatment were discussed with the patient, and it was decided to provide LANAP.

Seven months after treatment, a marked resolution of the osseous defect was observed (Fig. 16). Clinical photographs were not available.



**FIGURE 15** Case 6. Initial standard periapical radiograph illustrating the osseous defect (courtesy of Dr. Braden Seamons).



**FIGURE 16** Case 6. Seven-month post-treatment standard radiograph exhibiting marked resolution of the osseous defect (courtesy of Dr. Braden Seamons).

## Discussion

With the advent of the free-running pulsed Nd:YAG laser,<sup>††</sup> which has been specifically designed to address the treatment of periodontal pockets and the AL apparatus, the historically elusive goal of regeneration of cementum, PDL, and supporting bone has become a predictable reality. Historically, most surgical procedures focused on treating the effects of periodontal disease.

Techniques have evolved that have the potential to achieve more predictable outcomes by focusing on simultaneously

reversing the causes and the effects of periodontal disease. With successful application of these principles, one can anticipate producing greater longevity and ease of maintenance of the results. This, in turn, has the potential to produce enhanced clinical outcomes and better patient acceptance. LANAP is a well-defined treatment protocol, with human histologic validation and evidence of initial and long-term success. Continued research and careful observation will be necessary to sustain the clinical findings. ■

## Summary

**Why are these cases new information?**

- A limited number of clinical cases have been published with clinical and radiographic evidence of favorable results using the LANAP treatment protocol.

**What are the keys to successful management of these cases?**

- Strict adherence to the published methodology of the LANAP treatment protocol, with a clear understanding of the traditional goals and objectives of traditional periodontal therapy

**What are the primary limitations to success in these cases?**

- Deviation from the LANAP protocol
- Individual variability of patients

## Acknowledgments

The author thanks Dr. Murray Rabalais, Houma, Louisiana, for providing cases 1 and 2, Dr. Braden Seamons, Honolulu, Hawaii, for providing cases 3 and 6, and Dr. Matthew Heaton, Knoxville, Tennessee, for providing case 5. The author reports no conflicts of interest related to this case series.

### CORRESPONDENCE:

Dr. I. Stephen Brown, 220 South 16<sup>th</sup> St., Suite 300, Philadelphia, PA 19102. E-mail: istephenbrown@aol.com.

<sup>††</sup> PerioLase MVP-7 laser, Millennium Dental Technologies.



## References

1. US Department of Health and Human Services. Oral health in America: A report of the surgeon general (Executive summary). <http://www.nidcr.nih.gov/datastatistics/surgeongeneral/report/executivesummary.htm>. Published 2000. Accessed August 16, 2012.
2. Cohen DW. Graduate periodontology seminars. Philadelphia: University of Pennsylvania School of Dental Medicine, Department of Periodontics, Division of Advanced Dental Education; 1968-1970.
3. Fauchard P. *The Surgeon Dentist or Treatise on the Teeth* (in French). Lindsay L, translator. London: Butterworth; 1946.
4. Schluger S. Osseous resection: A basic principle in periodontal surgery. *Oral Surg Oral Med Oral Pathol* 1949;2:316-325.
5. Nabers CL. Repositioning the attached gingiva. *J Periodontol* 1954;25:38-39.
6. Nyman S, Lindhe J, Karring T, Rylander H. New attachment following surgical treatment of human periodontal disease. *J Clin Periodontol* 1982;9:290-296.
7. Gottlow J, Nyman S, Lindhe J, et al. New attachment formation in the human periodontium by guided tissue regeneration. Case reports. *J Clin Periodontol* 1986;13:604-616.
8. Urist MR. Bone: Formation by autoinduction. *Science* 1965;150:893-899.
9. Urist MR, Strates BS. Bone morphogenetic protein. *J Dent Res* 1971; 50:1392-1406.
10. Gregg RH 2nd, McCarthy D. Laser periodontal therapy: Case reports. *Dent Today* 2001;20:74-81.
11. Gregg RH 2nd, McCarthy D. Laser periodontal therapy for bone regeneration. *Dent Today* 2002;21:54-59.
12. US Food and Drug Administration. 510(k)s Final Decisions Rendered for July 2004 (PerioLase MVP-7, 510(k) number K030290). Available at: [http://www.accessdata.fda.gov/cdrh\\_docs/pdf3/k030290.pdf](http://www.accessdata.fda.gov/cdrh_docs/pdf3/k030290.pdf). Accessed: August 16, 2012.
13. Institute for Advanced Laser Dentistry, University of Colorado School of Dental Medicine. Denver: Lectures and Didactic Manuals, Evolutions 1-5.
14. Yukna RA, Evans GH, Vastardis S, et al. Human periodontal regeneration following the laser assisted new attachment procedure. Presented at: International Association of Dental Research/American Association for Dental Research/Canadian Association for Dental Research 82nd General Session; March 10-13, 2004; Honolulu, HI. Abstract 2411.
15. Yukna RA, Carr RL, Evans GH. Histologic evaluation of an Nd:YAG laser-assisted new attachment procedure in humans. *Int J Periodontics Restorative Dent* 2007;27:577-587.
16. Nevins ML, Camelo M, Schupbach P, Kim SW, Kim DM, Nevins M. Human clinical and histologic evaluation of laser-assisted new attachment procedure. *Int J Periodontics Restorative Dent* 2012;32: 497-507.

○ indicates key references.